

TREATMENT OF CERVICAL DISC HERNIATION

BACKGROUND

The cervical spinal cord may be considered the most important segment of the spinal cord, surpassing the thoracic and lumbar spinal segments. A herniated cervical disc is diagnosed when the inner core of a disc in the neck (cervical region) protruded, or leaks out of the disc, and compresses on an adjacent nerve root or spinal cord itself. A cervical disc herniation may occur suddenly from trauma, but most often it occurs over time from chemical and mechanical degenerative changes.

HISTORY

A 60-year-old man patient was diagnosed as cervical disc herniation by neurologic examination and MRI. The patient was advised to undergo surgery due to the negative impact of signs and symptoms upon his health. The patient agreed to surgery.

DIAGNOSIS

He was diagnosed with cervical disc herniation at the C5-6 level. While a cervical herniated disc may originate from some sort of trauma or neck injury, the symptoms commonly start spontaneously. The arm pain from a cervical herniated disc results because the herniated disc material pinches or presses on a cervical nerve, causing pain to radiate along the nerve pathway down the arm.



OSIMPLANT TITANOPEEK Stand Alone Cervical Cage was used in this surgery.

For more information please scan;



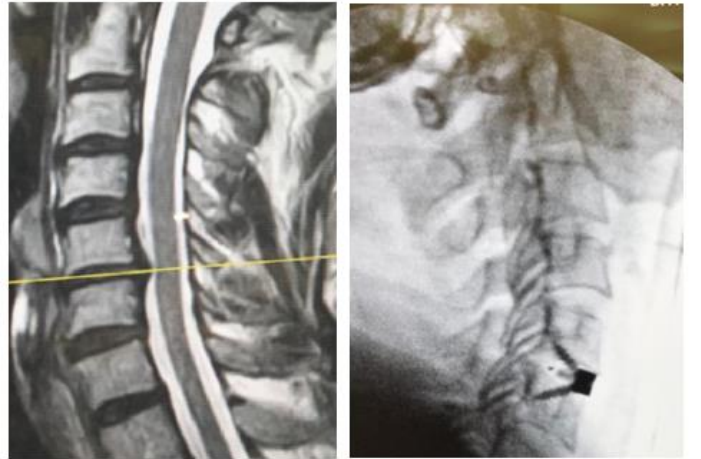
TREATMENT

The patient underwent C5-6 anterior cervical discectomy. Surgery was conducted using a standard anterior cervical approach and microdiscectomy. Under general anesthesia, the patient was placed in the supine position with the neck slightly extended. Through a right cervical incision, the target segment was exposed with the assistance of intraoperative C-arm X-ray. The anterior longitudinal ligament was opened, and the discectomy procedure was then performed. After sufficient decompression, an appropriately sized **OSIMPLANT TITANOPEEK Stand Alone Cervical Cage** was implanted into the intervertebral space under X-ray monitoring.



Prof. Dr. Uygur Er

PRE-TREATMENT & POST-OPERATIVE IMAGES



CONCLUSION

All complaints of the patient were eliminated. OSIMPLANT TITANOPEEK Stand Alone Cervical Cage can be used safely to obtain fusion after anterior cervical discectomy. The outcomes of this case indicate that OSIMPLANT TITANOPEEK Stand Alone Cervical Cage is an effective technique for treating degenerative cervical disc disease.