

CORRECTION OF NEUROMUSCULAR SCOLIOSIS

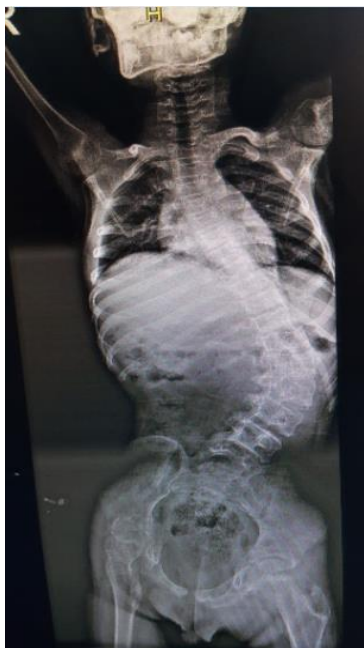BACKGROUND

Scoliosis is a common deformity in many types of neuromuscular disease. Severe spinal curvature can cause difficulty in sitting. Conservative and surgical treatment of neuromuscular scoliosis differs from idiopathic scoliosis, being more complex and with a higher complications rate. Scoliosis is a common consequence of neuromuscular diseases, including central nervous system disorders such as cerebral palsy and spinal cord injury; motor neuron disorders.

HISTORY

The patient is a 13-year-old with complaints of impaired sitting balance, compression of the heart and lungs, impaired rib and trunk mobility, abnormal head and upper extremity positioning. The patient has neuromuscular scoliosis and cerebral palsy diagnosis. The patient was advised to undergo surgery due to the long-term negative impact of signs and symptoms upon her health. The patient agreed to surgery. Cobb angle is measured 66, 7 degrees.

PRE-TREATMENT IMAGES



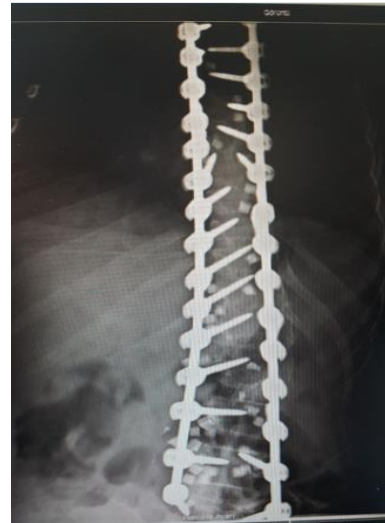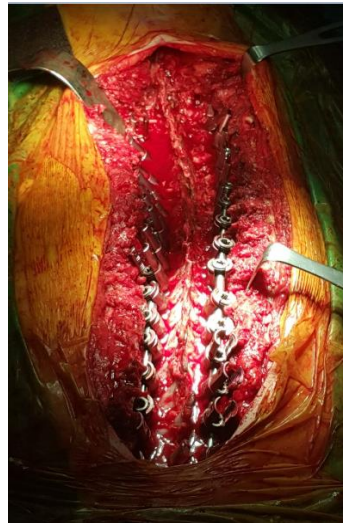TREATMENT

The patient underwent a T3 to L5 posterior spinal fusion with scoliosis correction. The patient underwent corrective surgery on his back with placement of screws and rods of **OSIMPLANT Deformity Set**. Transpedicular screws were placed from T3 to L5. Facetectomy performed from T11 to L5. Detoriation and correction were applied.



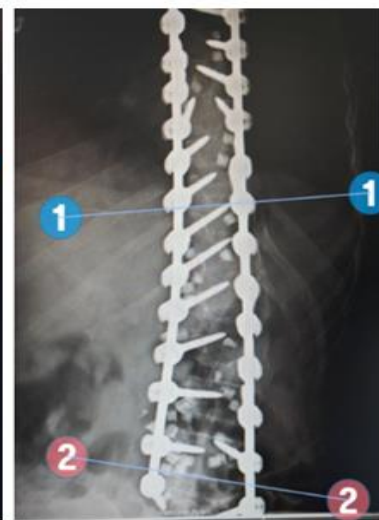
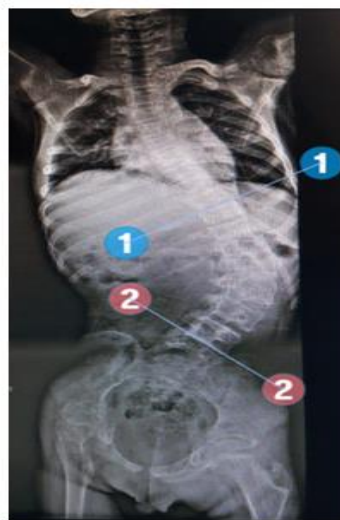
Assoc. Prof. M. Nurullah Ermiş

INTRAOPERATIVE AND POST-OPERATIVE IMAGES



CONCLUSION

Fusion problem is more common in neuromuscular scoliosis and bone fusion takes more time, so it is important to place screws to each levels. In this case, success was achieved by placing screws at all levels. The Cobb Angle was reduced to 13, 4 degrees immediately post-op.



Preop Cobb Angle 66,7 degree Postop Cobb Angle 13,4 degree