

Correction of Neuromuscular Scoliosis

SYMPTOMS

A 10-year-old female patient who has neuromuscular scoliosis diagnosis had presented to our outpatient clinic with difficulties during sitting. Patient had also a progressive thoracic scoliosis.

DIAGNOSIS

The sitting scoliosis X-ray image demonstrated a 127 degrees scoliosis at the thoracic spine. Patient could not sit proper and had imbalance while sitting. The difference between iliac crest was 10.5 cm.

TREATMENT

After a skin incision from T4 to S1 and visualization and incision of the paramedian fascia bilaterally the paravertebral muscles were dissected with periosteal preparation technique.

Transpedicular screws from T4 and S1 were placed bilaterally with free hand technique as possible. And double iliac screws were placed with the help of C-arm to strengthen the system. Neuromonitoring was used during the surgery.

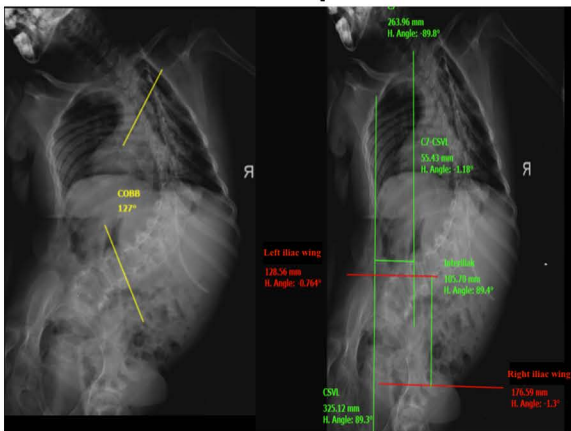
Multiple point Osteotomy were performed at the apex of the curve. After introducing curved rods and securing the locking screws, careful hemostasis, drainage and wound closed in layers.

‘The patient had a progressive thoracic scoliosis and also have an imbalance during sitting. We performed multipl Ponte osteotomies and placed screws from T4 to iliac with **OSIMPLANT Deformity Set** ‘



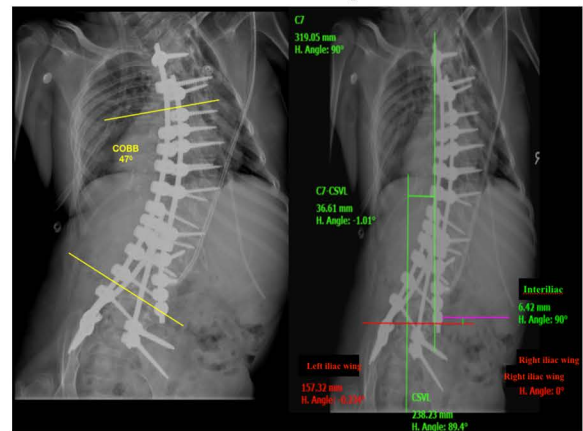
Ass. Prof. Dr. med. Onur Yaman

Pre-Op



Preop: Patient could not sit. The difference between iliac wings were 10.5 cm.

Post-Op



Postop: Patient could sit without any difficulty. IC line was less than 1cm after the surgery.