

CORRECTION OF LENKE TYPE 5 SCOLIOSIS

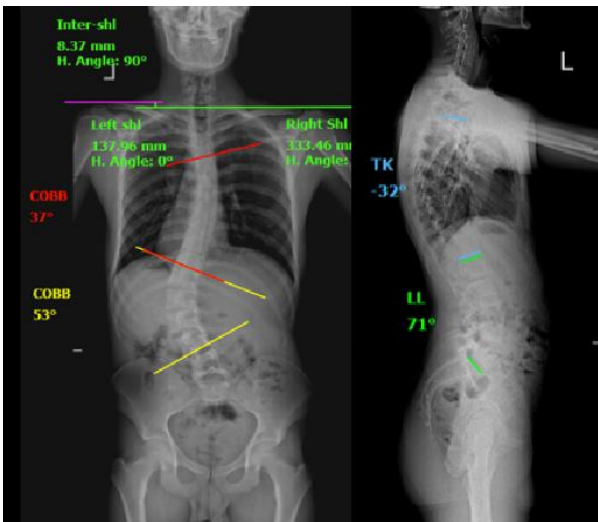
SYMPTOMS

A 26-year-old male patient who has had presented to our outpatient clinic with back pain. Patient was complaining about his cosmetic imaging. Patient has no neurological abnormality.

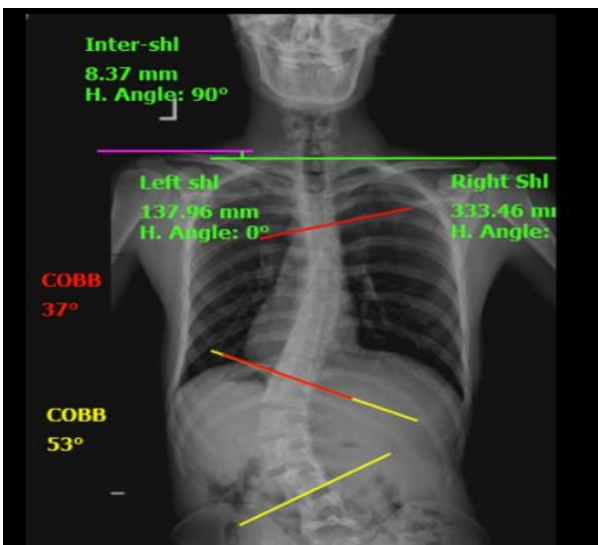
DIAGNOSIS

The X-ray image demonstrated a major scoliosis at the lumbar area with 53 degrees Cobb angle. Lateral bending films showed that the scoliosis angle was a non-structural curve.

PRE-TREATMENT IMAGES



A lumbar curve with 53 degrees at the lumbar and 37 degrees at the thoracic area.



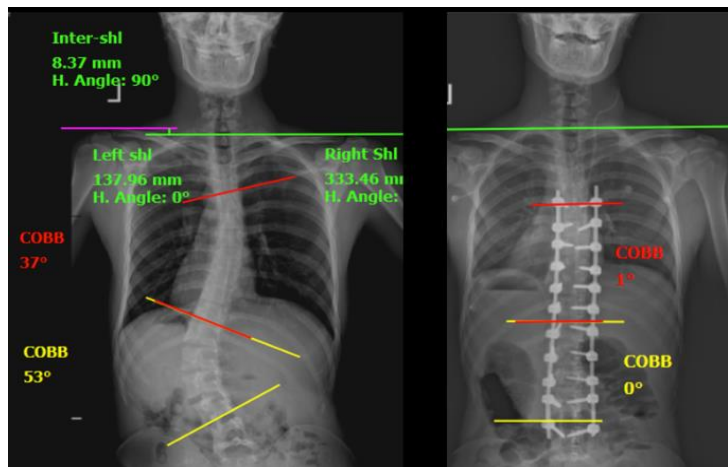
TREATMENT

The patient underwent corrective surgery on his back with placement of screws and rods of **OSIMPLANT Deformity Set**. After a skin incision between T6 and L4 and incision of the fascia subperiosteal muscle distraction has been performed to see the vertebrae. With free hand technique transpedicular screws were inserted bilaterally between T6 and L4. Ponte osteotomies were performed at the apex of the lumbar curve and 2 levels below and above at the apex. Left rod was placed with translation maneuver and then right rod was placed. Shoulder and iliac wing balance was controlled with C-arm. (Neuromonitoring has been done during the whole surgery). Careful hemostasis, drainage and wound closed in layers.



Ass. Prof. Dr. Med. Onur YAMAN

COMPARISON OF PRE AND POST-OPERATIVE IMAGES



CONCLUSION

Curve at the lumbar area and thoracic area and also hump at lumbar area was corrected with T6-L4 instrumentation.

