

## CORRECTION OF CONGENITAL KYPHOSIS

### BACKGROUND

Congenital kyphosis is a potentially devastating anomaly of the spine. Without treatment, the tendency is for severe, and sometimes catastrophic deformity. It is the most common etiology for spinal cord compression due to spine deformity. Late treatment is difficult and dangerous. It may compromise pulmonary function and cause paraplegia.

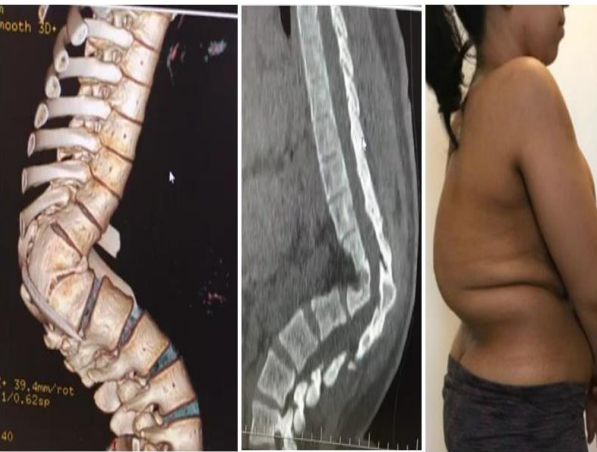### HISTORY

The patient is a 25-year-old female with complaints of pain and numbness of both legs. She has Congenital kyphosis diagnosis and she has T12-L1 hemivertebra. The patient was advised to undergo surgery due to the long-term negative impact of signs and symptoms of congenital kyphosis upon her health. The patient agreed to surgery.

### DIAGNOSIS

She was diagnosed with Congenital kyphosis; preoperative average kyphosis angle is measured 87, 2 degrees.

### PRE-TREATMENT IMAGES



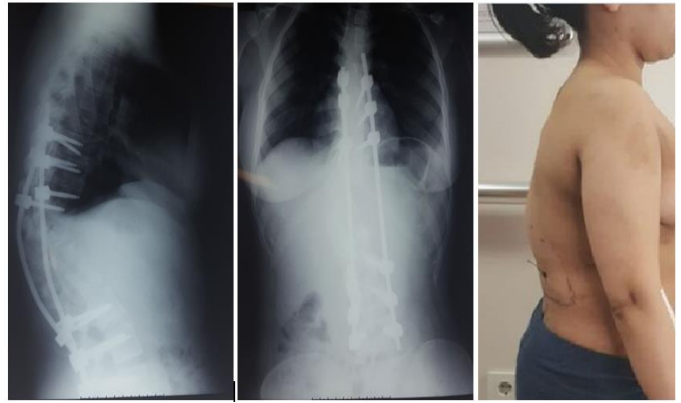
### TREATMENT

The patient underwent corrective surgery on her back with placement of screws and rods of **OSIMPLANT Deformity Set**. Transpedicular screws were implanted in T9-10-11 and L3-4-5 vertebral bodies. T2-L1 laminectomy was performed. Hemivertebra was excised. Osteotomy was performed until the anterior of the corpus. Correction was provided with the rods.



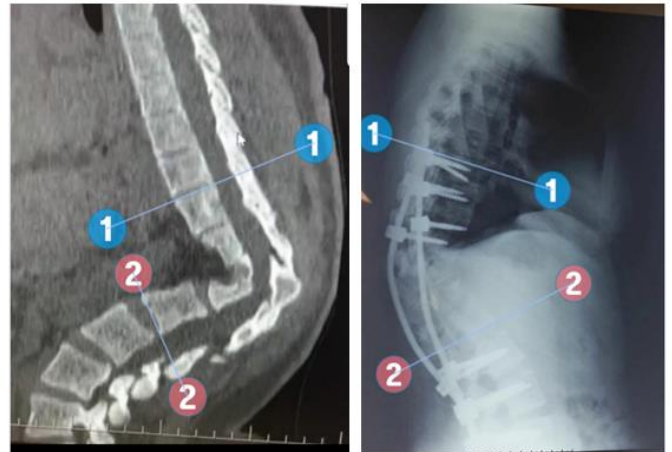
Assoc. Prof. M. Nurullah Ermiş

### POST-OPERATIVE IMAGES



### CONCLUSION

The patient reported feeling taller and more confident after surgery. The kyphosis angle was reduced to 43, 1 degrees (normal anatomic position) immediately post-op.



Preop Kyphosis Angle **87,2 °**

Postop Kyphosis Angle **43,1 °**