

CORRECTION OF ADOLESCENT IDIOPATHIC SCOLIOSIS

BACKGROUND

Scoliosis (AIS) is the most common spinal deformity seen by primary care physicians, pediatricians, and spinal surgeons. AIS is by far the most common type of scoliosis, affecting children between ages 10 to 18. Scoliosis is defined as a lateral and rotational curvature of the spine with an unknown origin. Scoliosis is diagnosed based on age of onset and clinical presentation. Physicians measure curve severity by Cobb's angle, which is marked on an X-Ray.

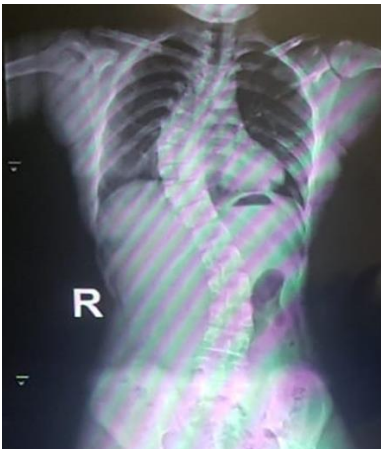
HISTORY

The patient is a 14-year-old female with complaints of scoliosis and back pain. She has scoliosis diagnosis. The patient was advised to undergo surgery due to the long-term negative impact of signs and symptoms of scoliosis upon her health. The patient agreed to surgery.

DIAGNOSIS

She was diagnosed with progressive adolescent idiopathic scoliosis.

PRE-TREATMENT IMAGES



TREATMENT

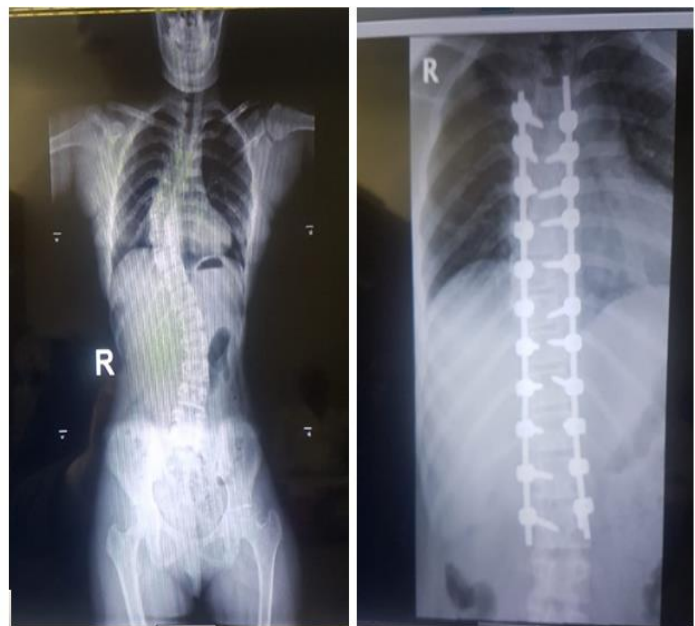
The patient underwent a T4 to L2 posterior spinal fusion with scoliosis correction. The patient underwent corrective surgery on her back with placement of 22 screws and 2 Rods of **OSIMPLANT Deformity Set**. After a skin incision from T4 to L2 and visualization and incision of the paravertebral muscles were dissected. Costotransverse joint release and derotation applied.



Prof. Ali Şehirlioğlu

CONCLUSION

The patient reported feeling taller and more confident after surgery.



For more information visit:

<http://osimplant.com/product/thoracolumbar/osi-spinal-fixation-system>

